

- Irwig, Fred.: Treatment of low back pain with injection, *Indust. Med.* 8:105, 1939.
- Judovich, B.: Low back pain, *Indust. Med.* 8:160, 1939.
- Koenig, W.: *Anaesthestirung und Quellung als Heilmittel*, Chirurg 17:18:680-683, 1947.
- Thieme, J. S., Jr., and Reed, E. F., Jr.: The use of Tubadil (repository injection of tubocurarine) in acute back strain, *Clinical Orthopaedics* No. 3, p. 172, Philadelphia, Lippincott, 1954.
- Lipow, Eugene G.: Slowly absorbed tubocurarine chloride in orthopedics, *A.M.A. Arch. Surg.* 66:312, 1953.
- Steindler, Arthur: The interpretation of sciatic radiation and the syndrome of low back pain, *J. Bone & Joint Surg.* 22:28, 1940.
- Steindler, Arthur, and Luck, J. V.: Differential diagnosis of pain low in the back, *J.A.M.A.* 110:106, 1938.
- Varco, S. A.: New method of pelvic traction for the relief of low back pain, *Surg., Gynec. & Obst.* 98:760, 1954.

Le Trattamento de Acute Dolores Infero-Dorsal

Summario in Interlingua

Es presentate un reporto del tractamento de impulsos dolorose; traction pelvic que promove un relaxation additional del musculos afflicte; corset orthopedic pro le supporto de tessuto traumatizzate; e exercitios equalmente applicabile a patientes de visita e a patientes hospitalisate. Es discutite le mesuras diagnostic e le principios e le tecnica del administration de agentes therapeutico. Le mesuras therapeutice include le uso de acute dolores infero-dorsal, le postural pro manatener le restaurate stato del correcte function mechanic.

Como resultado de iste integrate tractamento de acute dolores infero-dorsal, le patientes ha plus curte periodos de reconvallescencia e retorna plus promptemente a remunerabile formas de labor.

The Iliac Apophysis: An Invaluable Sign in the Management of Scoliosis

JOSEPH C. RISSER, M.D.*

Growth and completion of growth of the body is best shown by development of the bone growth centers, epiphyses and apophyses. The ossification of the carpal bones have long been used to indicate the bone age of a child. In infancy the time of femoral head ossification is also used to determine age. A delay in development usually is associated with a delay in metabolism.

The last ossification centers to appear and develop are the iliac crest apophysis and, finally, the apophysis of the ischial tuberosity. The latter is smaller, more difficult to visualize in roentgenogram and thus is of little significance, whereas the iliac apophysis is plainly visible and has a rather long element in its development.

An apophysis is a growing center which, as its name indicates, grows (physis) upon (apo) the mother bone. It differs from the epiphysis in that with the development of the ossification center all growth is completed. Coincident with the development of the iliac apophysis is the development of the excursion of ossification of the iliac apophysis across the iliac crest, the vertebral plates are completed, and spinal growth is finished. It is difficult to visualize the vertebral body growth plates and determine growth completion. Because of an almost simultaneous development of the iliac

The average time for completion of the iliac apophysis to its medial and posterior attachment is about 1 year. The shortest time was 7 months; the longest, 3 years. (Fig. 3)

The iliac apophysis may develop in fragments. After the usual capping or the appearance of ossification anteriorly and laterally on the iliac crest, further development may occur posteriorly, leaving a space, or gap, to be filled in later.

* Pasadena, Calif.

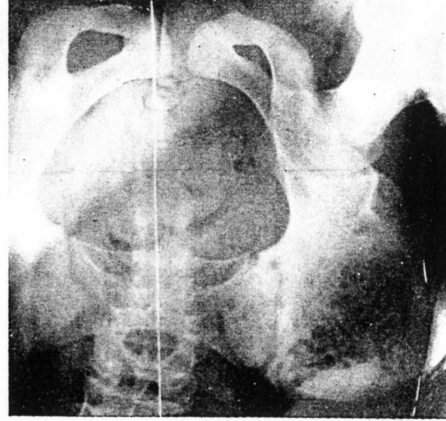


Fig. 1 (Left). Shows the appearance of the ossification of the iliac apophysis called *capping*. It can be seen over the right side of the pelvis anteriorly.

Fig. 2 (Right). Shows the posterior capping of the iliac apophysis. (See arrows over the pelvis.) This boy also had a congenital anomaly at 13. He was an untreated case, followed over a period of 10 years, during which period his curve increased over 20° until completion of the iliac apophysis.

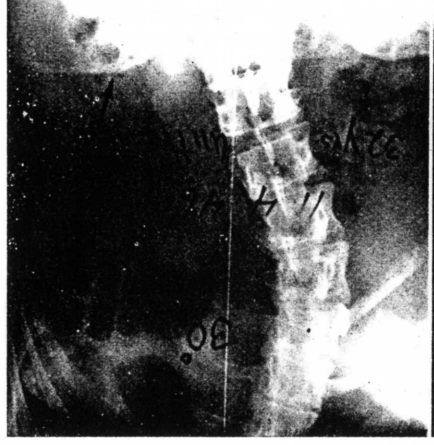
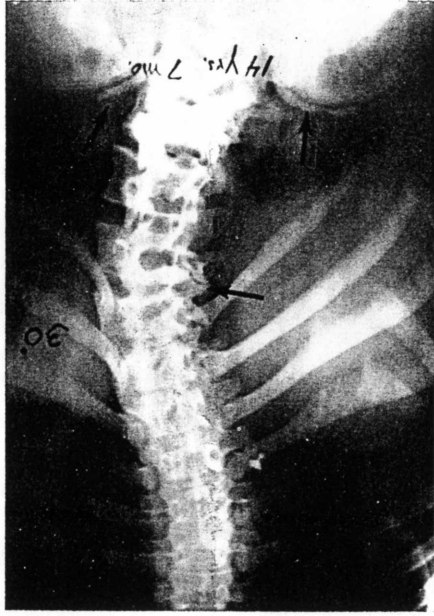

Fig. 3. (Left) Shows a girl of 16 with an untreated curve of 30°. Her apophysis has attached with a slight interruption of the excursion across the left pelvis. (See arrow.) (Right) Shows the girl over 15 years later. She is now a young adult. Although it has been 15 years since her last roentgenogram was taken, showing a curve of 30° and an attached iliac apophysis, her curve remained unchanged at 30°. The iliac apophysis has solidified and is now a part of the ilium. (See arrows.)

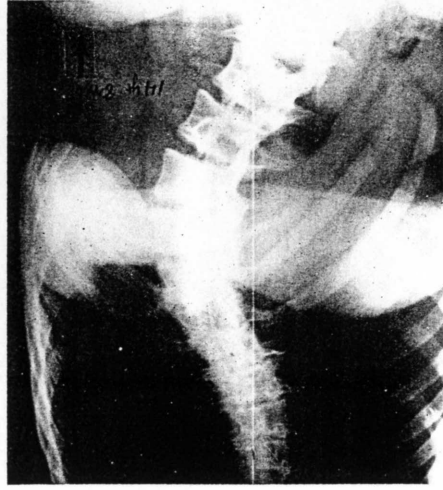


Fig. 4. Shows an iliac apophysis which was attached at about 75 per cent of the customary excursion. (See arrow over the left pelvis.) The curve did not increase after this attachment. This is called a short excursion of ossification of the iliac apophysis.

apophysis may occur. Earlier development usually takes place on the iliac crest of the high side of a pelvis seen with leg-length difference. Posterior ossification of the apophysis has been seen in the occasional congenital spinal deformity and in the infantile pelvis of some polios.

The excursion of ossification of the apophysis may be short and appear to attach to the ilium at a distance one half to three quarters across the iliac crest. In these cases the initial ossification center is thicker than usual. These are termed *short excursions* (Fig. 4). Vertebral growth usually is completed with the short excursion of the apophysis.

The average chronological age when the iliac apophysis is completed is 14 years in girls and 16 years in boys. It may occur as early as 10 or 11 years in girls and 13 or 14 in boys, and as late as 17 or 18 years in girls or 20 years in boys. Delayed development occurs in children in colder climates or in those whose metabolism is low. Early development of the apophysis occurs in warmer climates. These observations on the development of the iliac apophysis were begun in 1936 at the Los Angeles Orthopaedic Hospital and continued intensively for 10 years. The object of this study was to find some physiologic sign that would indicate the completion of vertebral growth. From a review of 296 untreated scoliotic cases made at the New York Orthopaedic Hospital from 1926 to 1936,* it was learned that scoliotic deformity became static with completion of vertebral growth (Fig. 5). This was determined by comparison of vertebral heights, standing and sitting, with measurements of the scoliotic deformity.† In this study it was found that spinal growth was slow in the period of 5 to 10 years of age; the average increase in scoliotic deformity was 4° to 5° a year, and the increase in sitting height averaged less than 1/2 inch a year, whereas in the preadolescent age, 10 to 15 years, the average increase in sitting height was 1 inch. In cases of marked nutritional deficiency there may be a rapid increase in the scoliotic deformity, even in untreated scoliotic cases (8 to 10 years).

The relationship between vertebral growth and scoliotic deformity can be explained by Hueter-Volkmann's epiphyseal pressure rule. This states that bone growth is retarded whenever pressure is increased, and is accelerated whenever pressure is diminished. Uneven pressure is possible when joint surfaces are not parallel, as seen in the convexity of the scoliotic spine. The vertebral growth plates are not easily visible in a roentgenogram; therefore, they did not furnish reliable information of vertebral growth. The completion of the excursion of

* Risser, J. C., and Ferguson, A. B.: Scoliosis: its prognosis, *J. Bone & Joint Surg.* 18:667, 1936.
 † Ferguson, A. B.: *South. M. J.* 23:116, 1930.

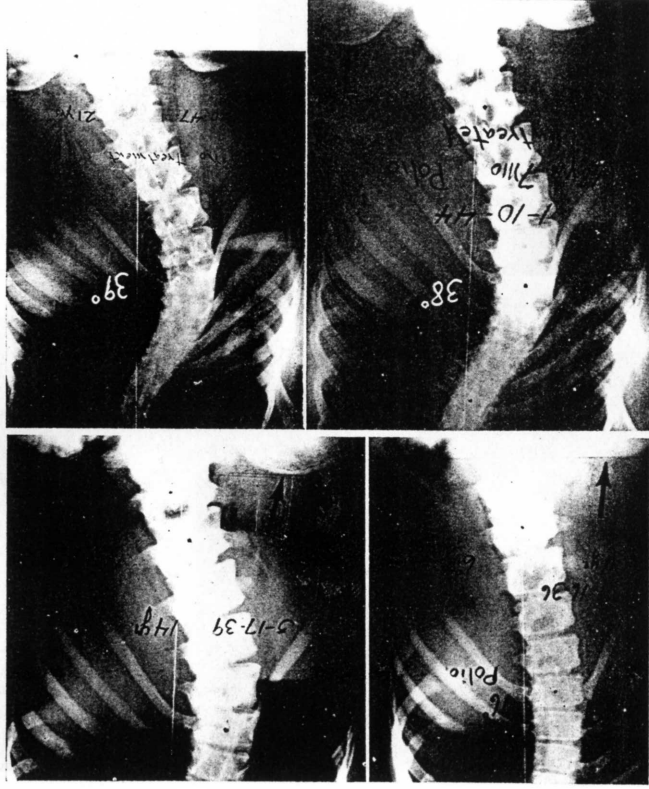


Fig. 5. (Top, left) Girl, 11 years of age, had polio at the age of 8, with mild appearance of the lateral curvature at the dorsolumbar junction. No iliac apophysis is seen at the age of 11. (Top, right) At the age of 14 it is noted that the iliac apophysis is complete, and there has been a noticeable increase in the deformity. (Bottom, left) At the age of 18½ there has been no further increase in the deformity since the completion of the iliac apophysis. (Bottom, right) This is an untreated case. Also at the age of 21 there has been no appreciable increase in the deformity since the completion of her iliac apophysis. (Risser, J. C.: J.A.M.A. 164:135)

the development of the ischial apophysis and increase in buttock size in fat girls.

Ten per cent of the cases showed no increase in scoliotic deformity, even though iliac apophysis was not complete and attached. This was especially difficult to determine in those cases with a short excursion of the iliac apophysis. During the past 20 years

3 cases have been reported which showed roentgenographic evidence of an increase in scoliotic deformity following completion, and even posterospinal attachment of the iliac apophysis. This increase in deformity continued only 3 to 6 months after the development of the apophysis and averaged 10°.

The coincidental development of the vertebral growth plates and the excursion of osseous height was very favorable. The correlation was not 100 per cent accurate. Variations were noted with fatigue of the patient and the addition to sitting height by

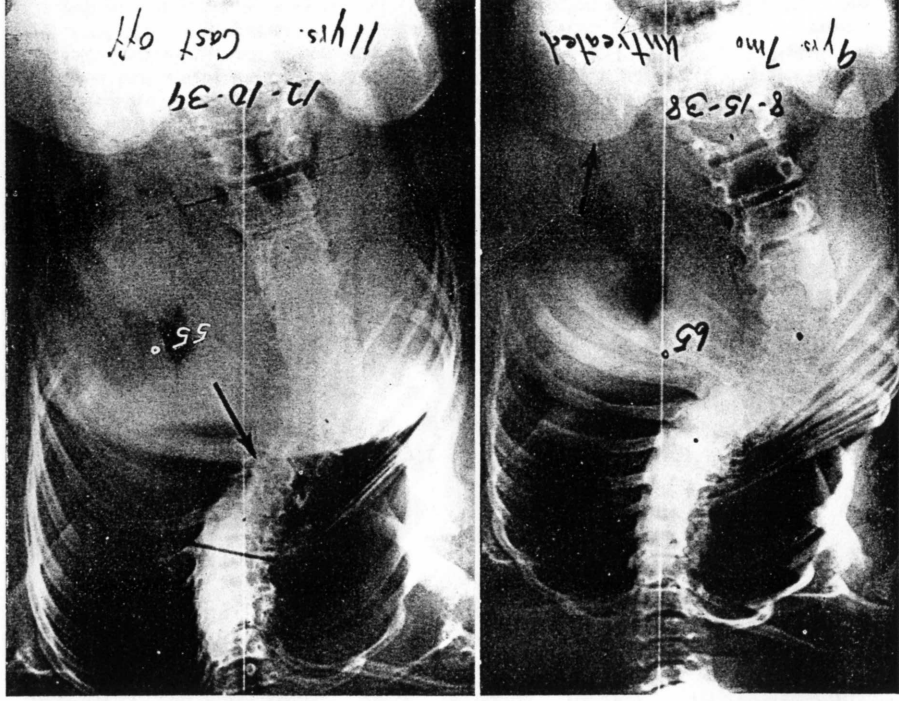


Fig. 6. (Left) Shows a 9-year-old girl with a severe scoliosis caused by a congenital anomaly at the eighth and the ninth dorsal vertebrae. The curve has not yet been treated. No iliac apophysis is present. (Right) Roentgenogram after correction and fusion of her dorsolumbar deformity. It is noted that there is a pseudarthrosis directly above the apex of the curve. The girl is 11 years old, and the iliac apophysis has not appeared. (Continued on next page)

etiology.

In the 2 years before the capping of the iliac apophysis, 75 per cent of the untreated cases increased from 10° to 35°. The deformity increases more slowly during the time when the iliac apophysis is completing its excursion. Two thirds of the untreated cases showed little appreciable increase (less than 10°) after the capping of the iliac apophysis. Any severe increase in the deformity during the excursion of the iliac apophysis was considered to be indicative of a nutritional deficiency.

It was important to use standing spinal roentgenograms for comparison. As the scoliotic grows older, flexibility decreases, even to ankylosis. Thus, the flexibility seen normally in the younger patient between standing and recumbent roentgenograms becomes less, and the recumbent deformity approaches the standing deformity. Therefore, there would be a gradual increase in the recumbent roentgenogram deformity with less and less flexibility until ankylosis was reached. At this time the recumbent deformity would have equaled the standing deformity. Increase in the scoliotic deformity after completion of vertebral growth has been

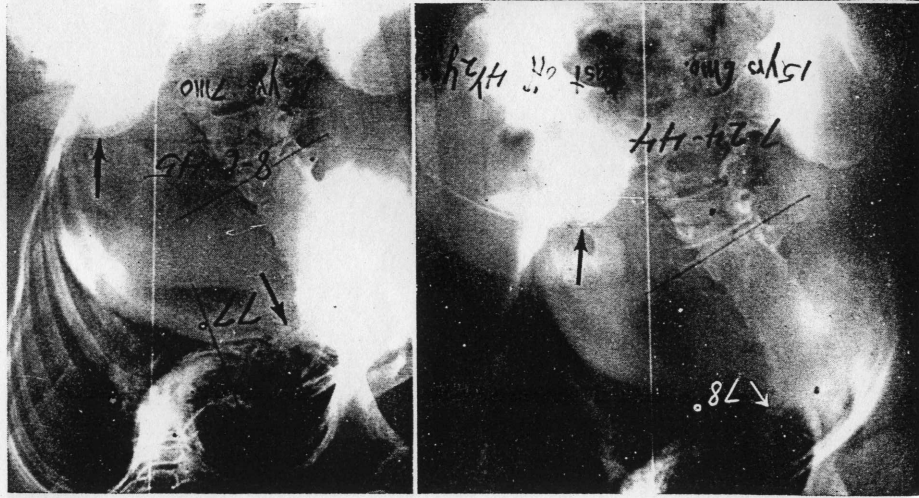
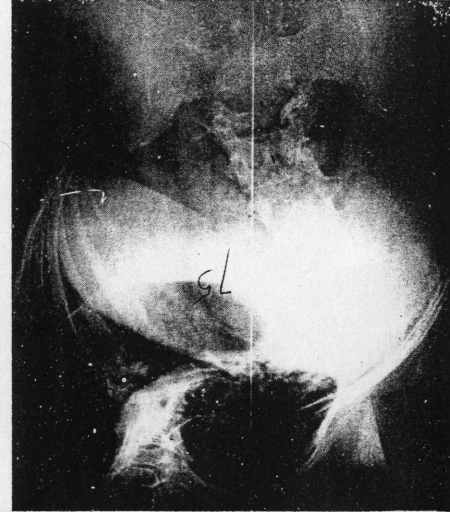


Fig. 6 (Continued). (Top, left) The cast

has been off 4½ years. The iliac apophysis has just attached. The pseudarthroses noted before have not been repaired. Thus, the curve has increased from 5° to 78° since the last support was removed. The curve now is greater even than it was before correction and fusion. (Original figure was 65°.) (Top, right) The iliac apophysis has been attached 1 year. The curve has not increased above the last figure of 78°, even though the pseudarthroses at D11-12 and D8-9 never were repaired. Hence, the pseudarthrosis will not cause further loss after the iliac apophysis has attached. (Bottom) Roentgenogram of the same girl, now 27 years of age, showing that there has been no increase in the deformity following the completion of her iliac apophysis at 15 years of age.



seen in very few cases. Superimposed pathology, such as marked osteoporosis, degenerative arthritis or disk degeneration, may allow an increase of lateral curvature. Common attached iliac apophysis. Conversely, the patient who has no visible iliac apophysis will require cast correction, surgical immobilization, or both, to prevent increasing deformity. In a certain number of cases surgically treated, the fusion may not be solid, or it may not be long enough to cover the area

of the greatest importance. In the management of the lateral curvature and of the progress of apophysis as a guide to the progress of Utilization of the development of the iliac spine.

ment of scoliosis, no treatment to prevent an increase in the lateral curve is needed for the individual whose roentgenograms show an attached iliac apophysis. Conversely, the patient who has no visible iliac apophysis will require cast correction, surgical immobilization, or both, to prevent increasing deformity.

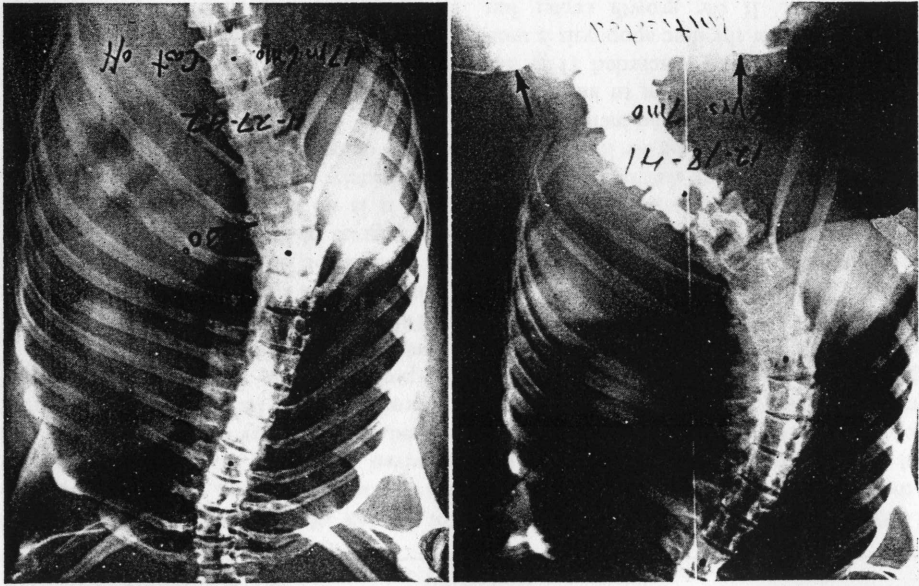
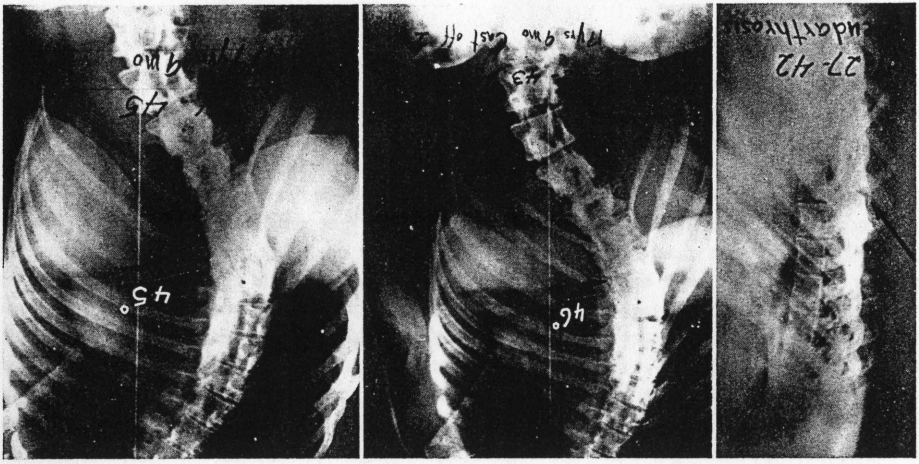


Fig. 7. (Top, left) A girl, 16 years old, whose iliac apophysis already is attached and is almost solid. Her lateral curve measures 54°. She has had no treatment. (Top, right) Her semibent jacket has just been removed, 8 months after surgical fusion had been accomplished from D4-L2. The maximum correction obtained in the turnbuckle jacket was from 54° to 22°. Already there has been a small loss of correction of 8° (22°-30°). A pseudarthrosis at D10-11 is noted. (Bottom, left) Lateral view of the spine. In this view the pseudarthrosis at D-10 and 11 can be seen. (See arrow.) (Bottom, center) Two years after the cast was removed, showing a deformity of 46°. There was a loss of correction at the point of the pseudarthrosis immediately after the cast was removed, but there was no further loss, as indicated by this roentgenogram, taken 2 years after the cast was off. The iliac apophysis being completed, there was no further growth and, therefore, no further propensity for increasing deformity, even though the pseudarthrosis. (Bottom, right) Two years later without any further loss of correction, because there has been no further growth.



of deformity (Figs. 6 & 7). In these cases, if the individual has not completed vertebral growth, there will be an increase in the lateral curve, even beyond its original deformity. But if the patient is through growing years, repair of the pseudarthrosis or additional fusion as indicated is imperative to prevent an increasing deformity.

In the occasional use of the localizer cast without surgery to prevent an increase in the lateral curve, it is important to know when the cast can be safely discarded (Fig. 8). The attachment of the iliac apophysis indicates as a criterion. If the growth center has completed its excursion of ossification, then it is safe to conclude that the cast treatment, for growth of the spine and of the lateral curve, can be stopped. But if the cast is removed before the iliac apophysis has attached, then we may expect a return of the deformity and an increase in the deformity in proportion to the anticipated spinal growth.

The significance of the iliac apophyses lies in its use as a more accurate criterion for the completion of vertebral growth and for the progress of the spinal curvature. Moreover, it is an invaluable aid that could be used widely in determining those patients whose deformity will remain static and, therefore, do not need preventative treatment. The patient could be told that the attachment of the iliac apophysis indicates the end of increase in his deformity. This information should save the patient needless worry and a considerable expenditure for unnecessary treatment.

Le Apophyse del Ilio: Un Importantissime Guida in le Trattamento de Scoliosis

Sumario in Interlingua

Depost plure annos on ha recognoscite que le deformitate scoliotic deveni static con osso, le crescentia vertebral es complete e le deformitate scoliotic ha devenite static. Iste constatation es importantissime pro pure rationes. (1) Ilio permitte un intelligente disposition del casos de scoliosis, viste que post le completion del crescentia nulle grande numero de casos—tanto tractate como etiam non-tractate—essava examinate con respecto al relation del sequente tres factores: (1) Le severitate del deformation. (2) Le clinic grandor vertical (a) in position erecte, (b) in genuflexion, e (c) section erecte. E (3) le excursion del ossification in le apophyse del ilio.

Le datos colligitte suffice a concluder que, quando le apophyse del ilio ha completate su excursion de ossification ab le cresta in basso reparate.

Le curso del passate decennio, un grande numero de casos—tanto tractate como etiam non-tractate—essava examinate con respecto al relation del sequente tres factores: (1) Le severitate del deformation. (2) Le clinic grandor vertical (a) in position erecte, (b) in genuflexion, e (c) section erecte. E (3) le excursion del ossification in le apophyse del ilio.

Le datos colligitte suffice a concluder que, quando le apophyse del ilio ha completate su excursion de ossification ab le cresta in basso reparate.

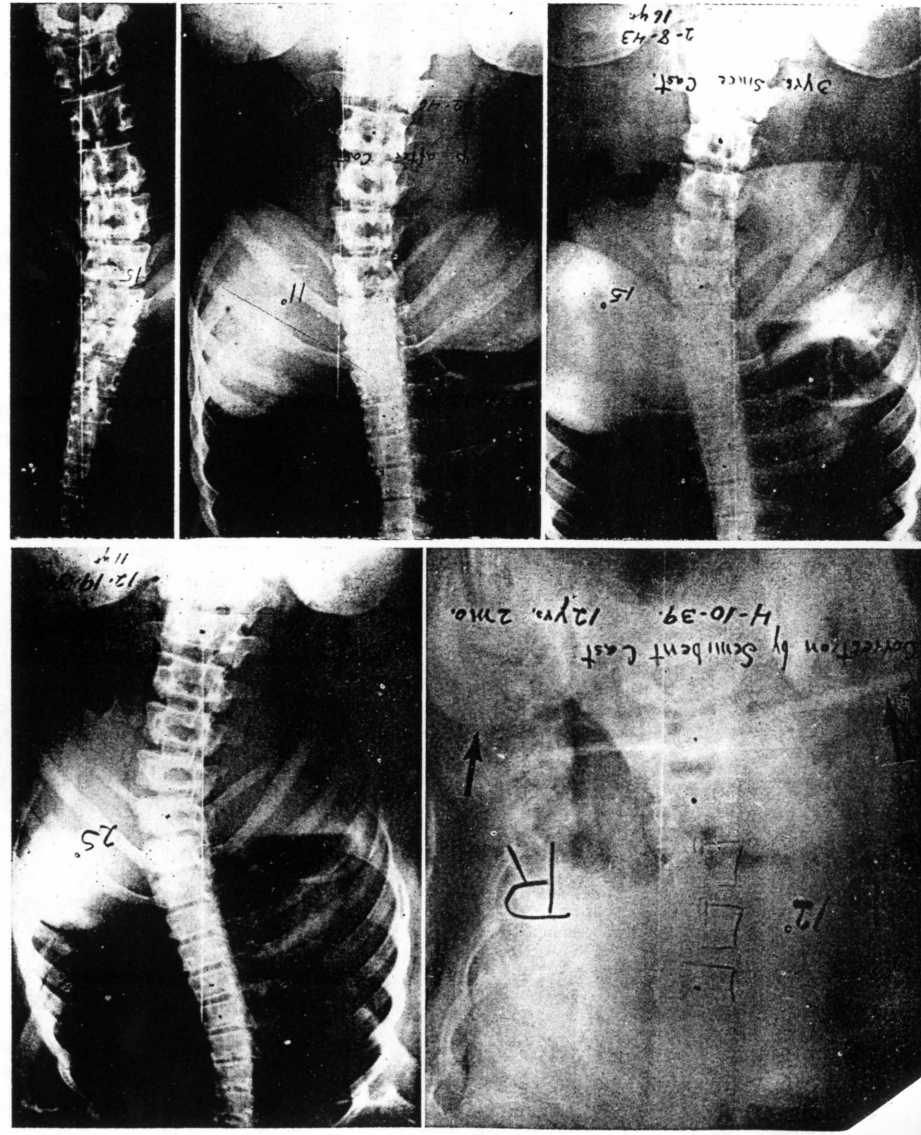


Fig. 8. (Top, left) An 11-year-old girl with 25° dorsolumbar curve. No iliac apophysis showing. (Top, right) Shows the girl in a semibent jacket with the curve bent against itself. The curve has been reduced from 25° to 12° to the opposite side. The iliac apophysis is well capped. (Bottom, left) Three years after cast. (Bottom, center) Six years after cast. (Bottom, right) Roentgenogram taken 18 years later shows that the patient is maintaining her correction at 15°, making a total of 10° maintenance of correction during the past 20 years. The lesson to be gained is that the iliac apophysis completion was maintained only by the cast and not by fusion. (Risser, J. C.: Am. Acad. Orthop. Surgeons Instructional Course Lectures 14:91, Ann Arbor, Edwards)